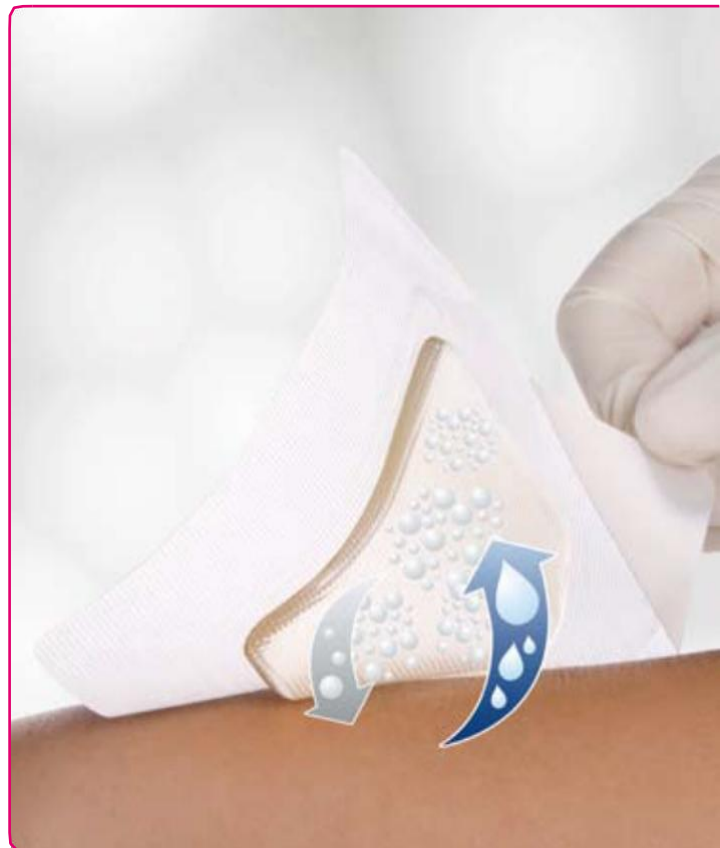



Antimicrobial wound care  
with glycerine-gel

Product is currently for sale outside U.S. only.  
Claims and intended use are currently not  
approved by in the U.S. by the FDA.

Wound healing with GLYCOcell®



## INTRO

### The modern wound care product line of GLYCOcell® ...

... provides a unique and new perspective on infection control and economical efficiency, two important features of today's patient care.

All products are composed of the same compact and transparent glycerine-gel in different forms with or without adhesive tapes.

Its major feature is a combination of antimicrobial action, absorbency, moisture regulation and transparency. It provides the optimal prerequisite of innovative wound care.

Since the introduction of antibiotics into clinical use, bacteria have protected themselves by developing antibiotic resistance mechanisms. Currently, there are increasing problems worldwide with multi resistant bacteria. These problems are especially evident within hospitals, where they frequently present as nosocomial epidemics.

High compliance with infection control measures and a prudent and more restrictive use of antibiotics are the key measures to prevent these epidemics.

GLYCOcell® wound care line is very effective without any local antibiotic or bactericidal use. It is able to inhibit the growth of bacteria and fungi based on a physical mode of action.



## ADVANTAGEOUS PRODUCT FEATURES AT A GLANCE

### THE GLYCERINE-GEL

- Effective infection control with proven bacteriostatic and fungistatic properties.
- The hygroscopic property assists in cleansing of the wound.
- The transparency of gel and tape provide a constant monitoring of the wound.
- The gel does not stick to the wound and allows a painless removal of the dressing.
- The gel absorbs wound secretion and maintains an optimal moist wound environment.
- The glycerine-gel keeps the skin smooth.
- The soft gel pad offers protective and comfortable cushioning.

### THE ADHESIVE TAPE

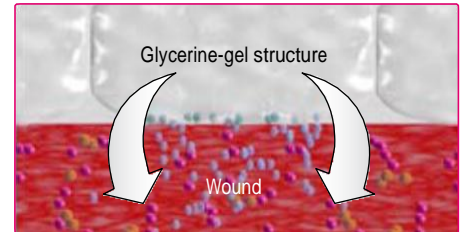
- GLYCOcell® products
  - The micro-perforated tape offers high moisture permeability.
  - The tape can be torn off.
  - The tape offers easy handling.
- GLYCOcell® SOFT products
  - The very thin, flexible and breathable tape offers waterproof protection.
  - The extremely elastic tape adjusts extraordinary well to body contours and adheres even on moving body regions.
  - The tape offers optimal comfort while moving.

## eXTRAORDINARY WOUND CARE

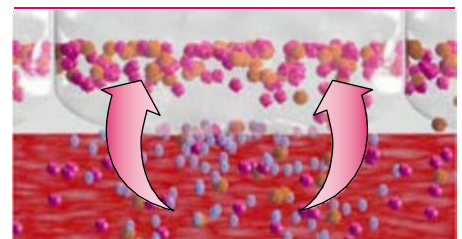
### PHYSICAL MODE OF ACTION

- excess moisture is withdrawn from the wound surface and securely locked into the gel structure due to the hygroscopic action of glycerine. At the same time glycerine is released to the surface of the wound. The interaction of both factors, the enclosure of exudate and the release of glycerine cause the effect that bacteria and fungi are inhibited in their growth. This moisture regulation mechanism provides an optimal environment for rapid wound healing. Since the glycerine-gel does not adhere with the wound surface, the new granulation tissue remains undamaged and the dressing change will be painless.

*Clinical Overview*  
*Dr. C. Mohrschladt*



Glycerine-gel keeps the skin moisturized and smooth



Absorbs excess moisture and locks it into the gel

## CLINICAL INDICATIONS

### GLYCOcell® SOFT 5x7, GLYCOcell® 10x10/5x7 & GLYCOcell® 5x7 GEL

- Surgical wounds, such as split-skin donor sites and skin grafts
- Superficial wounds in plastic surgery and prevention of scar tissue
- Traumatic wounds, such as abrasions as well as first-degree and second-degree burns
- Chronic, poorly healing, necrotic or infected wounds

### GLYCOcell® SOFT MiniFIX

- Surgical wounds, such as e.g. mole or wart removal
- Superficial wounds in plastic surgery and prevention of scar tissue
- Traumatic wounds, such as abrasions as well as first-degree and second-degree burns
- Chronic, poorly healing, necrotic or infected wounds

### GLYCOcell® FixoFORM

- Chronic, poorly healing, necrotic or infected wounds
- Traumatic wounds, such as abrasions, blistering
- Surgical wounds

### GLYCOcell® SOFT SondoFIX®

- Percutaneous stoma sites with temporary or permanent catheters

### GLYCOcell® SOFT VenFIX i.v.

- Dressing for percutaneous stoma sites of intravenous catheters, e.g.
  - Dialysis catheter
  - Apheresis catheter
  - Central venous line
  - Peripheral catheter

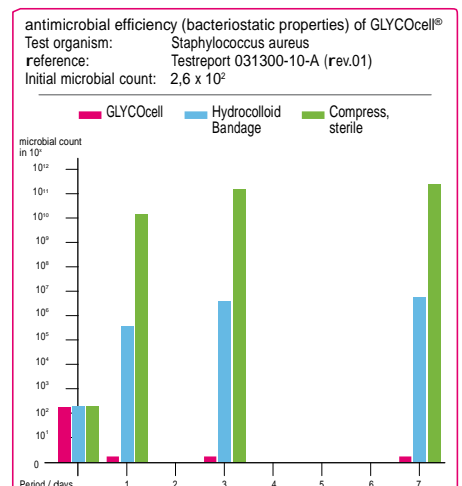
### GLYCOcell® SOFT MiniFIX i.v.

- Dressing for peripheral and pediatric intravenous catheters

## CLINICAL EVIDENCE

### IN-VITRO-TESTS CONFIRM

- Bacteriostatic & fungistatic efficiency by: *Staphylococcus aureus*\*, *Escherichia coli*\*, *Aspergillus niger*\*, *Pseudomonas aeruginosa*\*, *Streptococcus pyogenes*\*\*\*, *Enterococcus faecalis*\*\*, *Candida albicans*\*\*  
*Testreport\*031300-10-A[Rev.01], Medical Device Services, Gilching, 2004*  
*and Testreport\*\*074113-10, Medical Device Services, Gilching, 2008*
- Efficiency by MRSA colonization  
*Testreport042145-10, Medical Device Services, Gilching, 2004*



# New glycerine wound dressing modality for Peristomal PEG dressing: a simple, convenient, economical and better option

Multi center study, poster presentation DDW, 2009

Dietmar Borger<sup>1</sup>, Stefan Loitsch<sup>1,2</sup>, Yogesh Shastri<sup>1</sup>, Angelika Tessmer<sup>3</sup>, Nikolaos Stergiou<sup>3</sup>, Franz Hartmann<sup>1</sup>, Jürgen Stein<sup>1,2</sup>

1) Department of Internal Medicine, Katharina-Kasper-Hospital, Frankfurt am Main, Germany

2) Institute of Pharmaceutical Chemistry, J.W. Goethe University Frankfurt, Germany,

3) Department of Internal Medicine I, J.W. Goethe University, Frankfurt am Main, Germany

4) Department of Internal Medicine, Asklepios Kliniken Seligenstadt, Frankfurt am Main, Germany

## BACKGROUND AND AIMS

peristomal PEG (Percutaneous endoscopic gastrostomy) site infections are clearly the most common post procedure complication. despite prophylactic antibiotics, the routinely performed 'pull' type PEG placement technique has been associated with high peristomal infectious complications (3-30%; panigrahi et al., 2002).

Conventional wound care following PEG placement requires daily change of the wound dressing initially. new glycerin hydro gel wound dressing has been proposed to possess more effective antimicrobial properties. It can be kept for up to 7 days, eliminating the need for daily change of dressings of the PEG wound.

The aim of the present study was comparing the occurrence of peristomal infections, and the frequency of change of wound dressing between the groups of patients offered conventional vs. the new glycerine wound dressing.

## PATIENTS AND METHODS

SondoFIX® (Medi-Globe GmbH, Germany) is a triangular glycerine wound dressing equipped with a pre-cut slit which facilitates its easy fixation around the PEG catheter. A hypo-allergenic, semi-transparent and cushioned plaster is gelled allowing easy application and wound inspection.

68 patients undergoing PEG were prospectively evaluated from January 2007 to November 2008, 34 patients received a conventional wound dressing while 34 were offered the SondoFIX® wound dressing. Both patient groups were equally matched for age, sex, and weight. The PEG site was assessed for wound inflammation on the day after the procedure and subsequently 1, 2 and 4 weeks post procedure using the validated wound scoring system of Jain et al. (1987). A Wound score of more than 8 or the presence of frank pus was regarded as a major infective complication.

## RESULTS

At the end of the first and second week, a statistical significant reduction of the mean wound score was shown on patients with glycoGel wound dressing, compared to those with a conventional wound dressing (1st week:  $1.64 \pm 1.6$  and  $3.12 \pm 2.69$ ,  $p < 0.0082$ ; 2nd week:  $1.37 \pm 1.11$  and  $2.53 \pm 2.37$ ,  $p < 0.023$ ). After 4 weeks, the wound score in both groups was comparable.

The patients in the SondoFIX® group had  $4.56 \pm 1.6$  changes of the wound dressing in 4 weeks, while patients with the conventional wound dressing received  $22.63 \pm 6.6$  wound dressings ( $p < 0.000001$ ). One of the patients with conventional wound dressing developed a major peristomal infection. Three patients in the SondoFIX® group died due to underlying disease. The wound dressing of five patients in the SondoFIX® group had to be removed ahead of time, in three cases due to excessive wound secretion, in the other two cases due to an local allergic reaction that seemed to be caused by the gel.

## CONCLUSION

The new glycerine wound dressing significantly reduces peristomal PEG site wound infections as compared to conventional wound dressings.

Also, the glycerine wound dressing requires about 5 times less frequent changes of the dressing making it simpler, more convenient, less labor intense and an economical option for wound management post PEG.

As a minor limitation glycoCell wound dressings are contraindicated by excessive wound secretion and may cause minor allergic reactions.

## REFERENCES

Panigrahi H, Shreeve Dr, Tan WC, Prudham R, Kaufman R. Role of antibiotic prophylaxis for wound infection in percutaneous endoscopic gastrostomy (PEG): result of a prospective double blind randomized trial. J Hosp Infect. 2002;: 312-5.

Jain NK, Larson de, Schroeder KW, Burton DD, Cannon KP, Thompson RL, et al. Antibiotic prophylaxis for percutaneous endoscopic gastrostomy. A prospective, randomized, double-blind clinical trial. Ann Intern med 1987; 107:824-828.

# Improved PEG\* stoma care by using a glycerine-gel dressing (SondoFIX®)

A clinical application

*N. Stergiou, T. Mindermann, M. Klump,*

*Asklepios Klinik Seligenstadt, Germany, Unit for internal medicine*

## INTRODUCTION

The goal of this clinical application is to examine the safety of a glycerine hydro gel dressing (SondoFIX®) on initial wound care by a new percutaneous endoscopic gastrostomy (PEG) in reference to the occurring complications especially by local infections.

## METHOD

In a test period of 19 month (6/2005-12/2006) 60 patients (20 male, average age 76,9 years [35-95 years]) were with a PEG to ensure enteric feeding. The stoma dressing used in this trial was a glycerine hydro gel dressing (SondoFIX®), applied between the holding plate and the abdominal stoma site for duration of 7 days. no dressing changes were performed in this period of time. After 36 to 50 hours of the invasive procedure, the PEG tubing was mobilized by 1,5 to 2 cm with the special designed gel dressing still in place. The removal of the dressing took place after 7 days to assess the stoma site in concern of local inflammatory reactions.

## RESULTS

During the examination period, 2 out of 60 patients had a notable local reddening at the stoma site by the application after seven days. 0 out of 60 cases had serious infections with purulent discharge or signs of septical complications. A procedure related abdominal wall haematoma, a local bleeding after PEG procedure and bleeding due to self-manipulation of the PEG tubing by the patient were presented. In one case an allergic reaction due to the fixating adhesive tape of the glycerine hydro gel dressing occurred. The seven day mortality was 8,3% (5/60), whereas no methodical related deaths and furthermore no mortalities through infection were noted.

## SUMMARY

Following a new percutaneous endoscopic gastrostomy, the initial treatment with a glycerine hydro gel stoma dressing (SondoFIX®) for a duration of 5-8 days presents a save method without side effects. A routine dressing change and wound inspection during the first 5-7 days can be done if no clinical evidence of an existing infection is presented. This method seems reasonable validated under the points of view of economical aspects and patient comfort.



\*percutaneous endoscopic gastrostomy



# 1<sup>st</sup> CASE

## BACKGROUND

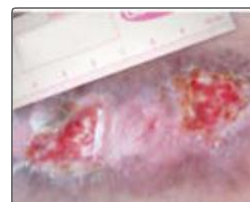
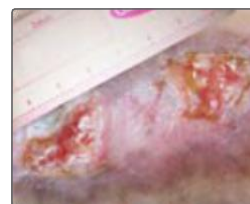
- male, 73 years
- 40 years of DM history, on hypoglycemic treatment
- Scalding wound on right leg since October 25, 2008

## WOUND

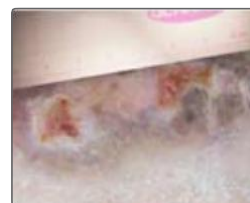- Size: 2 x 2 cm, with some purulent discharge
- No odor
- Swelling, redness
- Bacteria culture: (+) Staphylococcus epidermidis

## TREATMENT

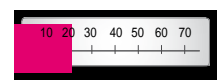
- Debridement & applying GLYCOcell® on November 10, 2008
- Dressing is changed on November 15, 2008
  - Wound size: 1 x 1 cm
  - No purulent discharge
  - Bacteria culture: (-) negative
  - Graduate growth: ++



Wound size: 1x 0.5 cm on Nov 20, 2008  
Graduate growth: +++



Wound healed on Nov 25, 2008



Wound healing in 15 days

# 2<sup>nd</sup> CASE

## BACKGROUND

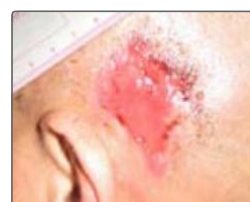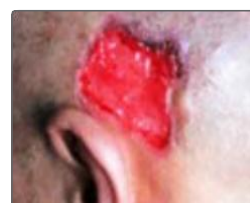- Male, 45 years
- 5 years of dm history, on Insulin treatment
- An abscess on skull for 2 weeks
- Wound did not heal

## WOUND

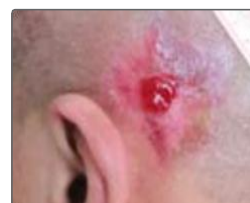- Size: 6 x 4 cm, with some purulent discharge
- No odor
- Swelling, redness & tender
- Bacteria culture: (+) enterococcus
- Graduate Growth: +++

## TREATMENT

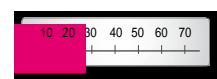- Debridement & applying GLYCOcell® on October 10, 2008
- Dressing changed on October 15, 2008
  - Wound size: 4 x 3.5 cm
  - No purulent discharge
  - Bacteria culture: (-) negative
  - Graduate growth: +++



Wound size: 3.5 x 3 cm on Oct 20, 2008



Wound healed on Oct 30, 2008



Wound healing in 20 days

### 3<sup>rd</sup> CASE

#### BACKGROUND

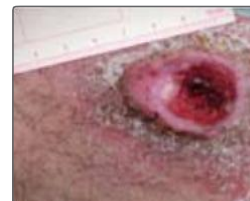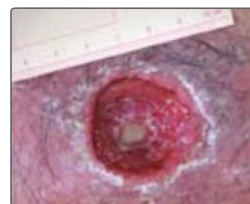- Male, 45 years
- 17 years of DM history, under hypoglycemic treatment
- An abscess on left leg with pain and fever for 3 months
- Wound did not heal after debridement

#### WOUND

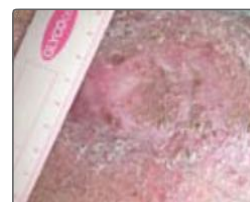- Size: 4 x 3.5 cm, with some purulent discharge
- No odor
- Swelling, redness, tender
- Bacteria culture: (+) Staphylococcus epidermidis

#### TREATMENT

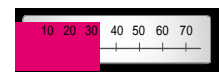- Debridement & applying GLYCOcell® on December 13, 2008
- Dressing is changed on December 20, 2008
  - Wound size: 3.5 x 3 cm
  - Bacteria culture: (-) negative
  - Graduate growth: ++



Wound size: 2x2 cm on Dec 27, 2008



Wound healed on Jan 8, 2008



Wound healing in 26 days

### 4<sup>th</sup> CASE

#### BACKGROUND

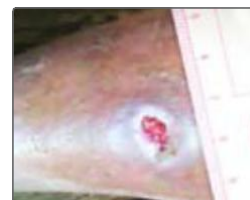- Male, 78 years
- 20 years of DM history, on hypoglycemic treatment
- Subcutaneous hematoma on left leg after injury

#### WOUND

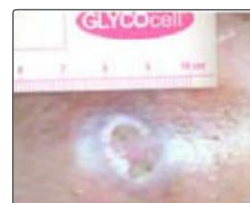- Size: 4 x 3 cm, with some purulent discharge
- No odor
- Swelling
- Bacteria culture: (+) Pseudomonas aeruginosa
- Graduate Growth: ++

#### TREATMENT

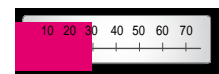
- Debridement & applying GLYCOcell® on October 15, 2008
- Dressing changed on October 22, 2008
  - Wound size: 3.5 x 3.5 cm
  - No purulent discharge
  - Bacteria culture: (-) negative
  - Graduate growth: +++



Wound size: 1.5 x 2 cm on Oct 30, 2008



Wound healed on Nov 8, 2008



Wound healing in 24 days

## 5<sup>th</sup> CASE

### BACKGROUND

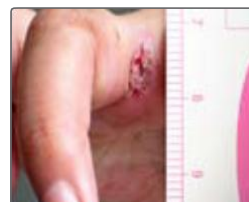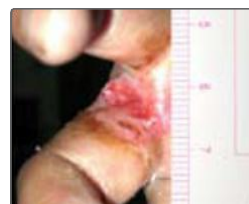- Female, 72 years
- 30 years of DM history, on hypoglycemic treatment
- An abscess between forefinger and middle finger, swelling and pain for 3 days

### WOUND

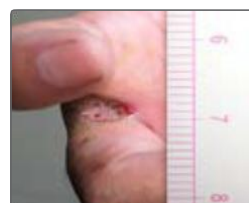- Size: 1 x 1.5 cm, with some purulent discharge
- No odor
- Swelling
- Bacteria culture: (+) enterobacter

### TREATMENT

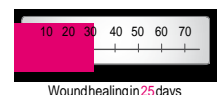- Debridement & applying GLYCOcell® on October 13, 2008
- Dressing is changed on October 20, 2008
  - Wound size: 1 x 1 cm
  - No purulent discharge
  - Bacteria culture: (-) negative
  - Graduate growth: +++



Wound size: 0.5 x 0.5 cm on Oct 27, 2008



Wound healed on Nov 7, 2008



## 6<sup>th</sup> CASE

### BACKGROUND

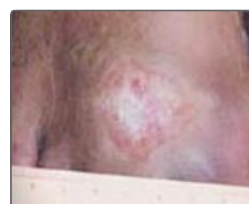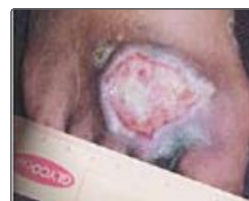- Male, 58 years
- 20 years of DM history, on hypoglycemic treatment
- A scalding wound on the dorsal pedal with swelling and pain, fever for 2 weeks
- Wound did not heal
- No improvement after infection control treatment

### WOUND

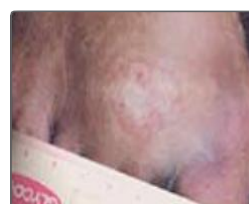- Size: 5.5 x 5 cm, with some purulent discharge
- no odor
- Swelling
- Bacteria culture: (+) proteobacteria

### TREATMENT

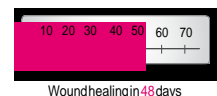- Debridement & applying GLYCOcell® on October 13, 2008
- 2008 dressing changed on October 20, 2008
  - Wound size: 4.5 x 5 cm
  - No purulent discharge
  - Bacteria culture: (-) negative
  - Graduate growth: +++



Wound size: 0.5 x 0.5 cm on Nov 8, 2008



Wound healed on Dec 1, 2008





## 7<sup>th</sup> CASE

### BACKGROUND

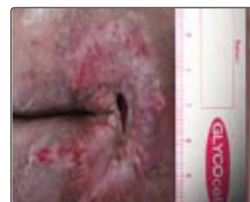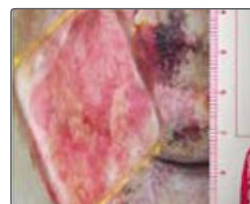
- Male, 59 years
- 15 years of DM history, on Insulin treatment for 10 years
- Cervical fracture at V, VI
- Paraplegia caused by plump injury
- Pressure Sore on Sacrococcygeal joint for 12 months

### WOUND

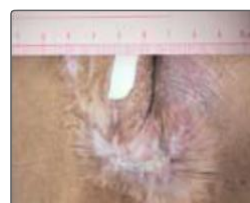- Size: 7 x 6 cm, with some pus exudates
- High superficial skin temperature, no odor
- Swelling, redness, tender
- Bacteria culture: (+) Staphylococcus aureus
- Graduate growth: ++

### TREATMENT


- Debridement & applying GLYCOcell® on October 3, 2008
- Dressing is changed every 3 to 4 days
- On November 3, 2008
  - Wound size: 2 x 1 cm
  - no purulent exudates and inflammation sign
  - Granulation
  - Bacteria culture: (-) negative



Wound size: 1.5 x 0.5 cm on Nov 10, 2008



Wound healed on Nov 24, 2008



Wound healing in 52 days

## 8<sup>th</sup> CASE

### BACKGROUND

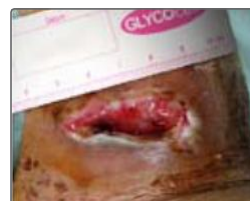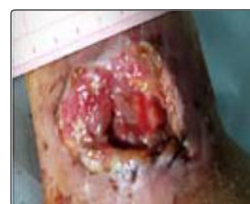- Female, 67 years
- 15 years of DM history, on hypoglycemic treatment
- Open fracture on left ankle on may 15, 2008
- Wound infection after internal fixation

### WOUND

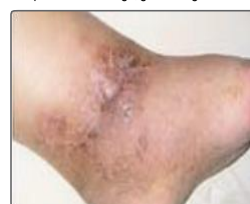- Size: 5.1 x 4.5 cm, with large purulent discharge
- High superficial skin temperature
- Odor, swelling, redness, tender
- Bacteria culture: (+) Staphylococcus aureus
- Inflammatory graduate growth at bottom

### TREATMENT

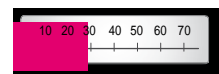- Debridement & applying GLYCOcell® on September 21, 2008
- Dressing changed on September 28, 2008
  - Wound size: 4.2 x 2 cm
  - Some purulent exudate
  - No inflammation sign
  - Bacteria culture: (-) negative
  - Granulation growth: ++



Wound size: 3.5 x 2 cm on Oct 4, 2008  
no purulent discharge, graduate growth: +++



Wound healed on Oct 12, 2008



Wound healing in 21 days

## 9<sup>th</sup> CASE

### BACKGROUND

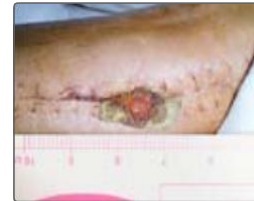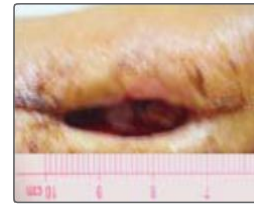- Female, 65 years
- 20 years of DM history, on hypoglycemic treatment
- Left tibial plateau fracture
- Internal fixation done on September 12, 2008
- Wound infection after operation

### WOUND

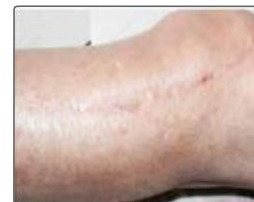- Size: 2.5 x 0.5 cm, with some purulent discharge
- High superficial skin temperature
- No odor, swelling, redness, tender
- Swelling
- Bacteria culture: (-) negative
- No graduate growth at bottom

### TREATMENT

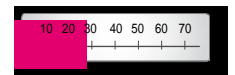- Debridement & applying GLYCOcell® on September 18, 2008
- Dressing is changed on September 25, 2008
  - Wound size: 2 x 0.5 cm
  - No purulent exudates
  - Granulation growth: ++



Wound size: 1.5 x 0.5 cm on Oct 2, 2008



Wound healed on Oct 9, 2008



## 10<sup>th</sup> CASE

### BACKGROUND

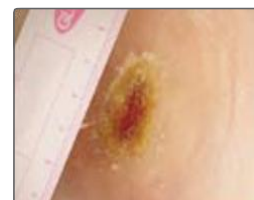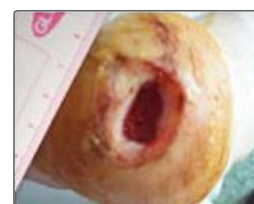- Female, 24 years
- 2 years of DM history, on insulin treatment
- Swelling, redness and pain on left heel for 2 weeks
- No improvement after infection control treatment
- Wound did not heal after debridement

### WOUND

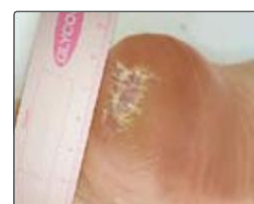- Size: 3.5 x 1 cm, with some purulent discharge
- No odor
- Swelling
- Bacteria culture: (+) Staphylococcus epidermidis

### TREATMENT

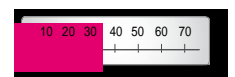
- Debridement & applying GLYCOcell® on September 13, 2008
- Dressing changed every 3 to 4 days
- On September 27, 2008
  - Wound size: 0.5 x 0.5 cm
  - No purulent exudates
  - Bacteria culture: (-) negative
  - Granulation growth: +++



On Oct 5, 2008



Wound healed on Oct 12, 2008



# 11<sup>th</sup> CASE

## BACKGROUND

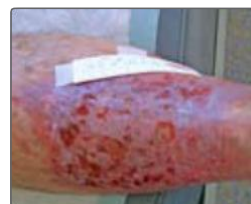- Male, 44 years
- Smoker
- DM II, post thrombotic syndrome
- Multiple ulcerations on right leg which did not heal

## WOUND

- Size: 2.4 x 1 x 0.3 cm; 10 x 6 x 0.3 cm
- Signs of ischemia
- Swelling, redness
- Bacteria culture: (-) negative

## TREATMENT

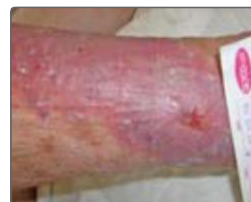- 4 months prior treatment with pavilon gel, Biatain and Aquacell dressings with no change of wound condition or pain relieve
- Treatment with GLYCOcell® 10x10 without adhesive edges
- Dressing renewed every 3rd day initially, then every 4-5th days
- After 3 month of treatment with GLYCOcell® the multiple ulcerations have improved remarkably. Healing progresses rapidly in the last month. The patient was free of pain and able to mobilize to the best of his ability.



Treatment with GLYCOcell®  
on Dec 14, 2007



On February 1, 2008



Wound healed on February 15, 2008



# 12<sup>th</sup> CASE

## BACKGROUND

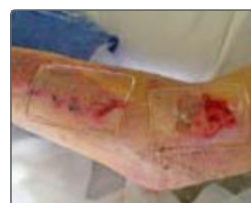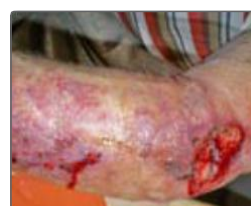- Male, 89 years
- Anticoagulant therapy
- DM II
- Traumatic skin tears with fractured left elbow

## WOUND

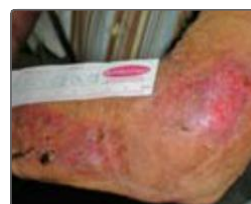- Size: 3 x 2 cm and 1 x 2 cm with light bleeding of the wounds
- Hematoma of surrounding area
- Swelling
- Bacteria culture: (-) negative

## TREATMENT

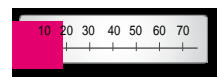
- Cleansing of wound and applying GLYCOcell® 5x7 GEL on march 29, 2009
- Dressing changed on April 2, 2009
- Wound size: 2 x 2 cm and 1 x 1 cm no
- Drainage
- Wound healed on April 9, 2009



On April 2, 2009



Wound healed on April 9, 2009



GLYCOcell® has a variety of wound care dressings with their unique features to care for acute, infected and chronic wounds.



See detailed application videos under:

[www.glyocell.info](http://www.glyocell.info)

## Contact

Information / Customer Service / Distribution:

Advanced Biomedical Concepts  
5303 56th Commerce Park Blvd · Tampa Florida 33610  
U.S.A.

☐ 813-626-2111 · ☎ 813-626-2111  
info@glyocell.info · www.glyocell.info